

17. Several criteria are applied to the naming of muscles. These are provided in Column B. Identify which criteria pertain to the muscles listed in Column A and enter the correct letter(s) in the answer blank.

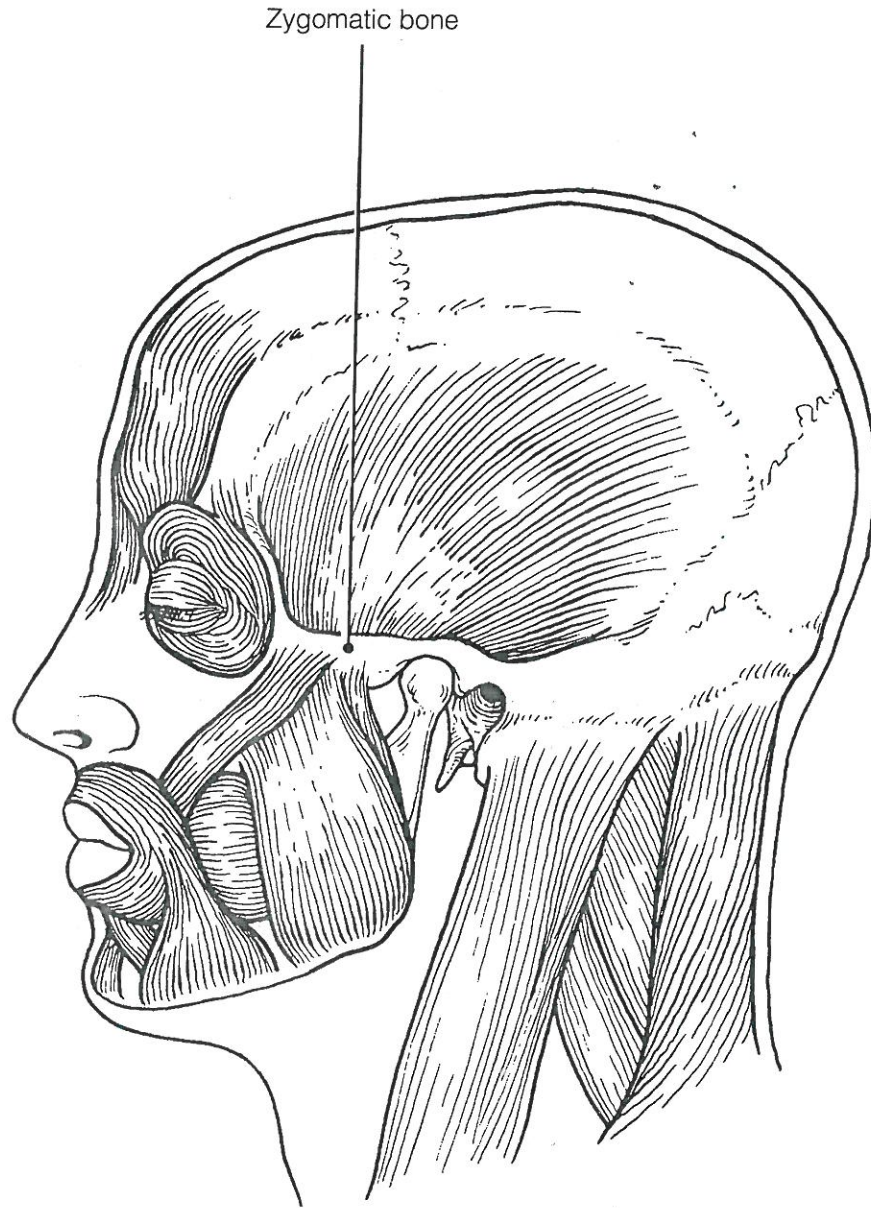
<b>Column A</b>	<b>Column B</b>
_____ 1. Gluteus maximus	A. Action of the muscle
_____ 2. Adductor magnus	B. Shape of the muscle
_____ 3. Biceps femoris	C. Location of the muscle's origin and/or insertion
_____ 4. Transversus abdominis	D. Number of origins
_____ 5. Extensor carpi ulnaris	E. Location of muscle relative to a bone or body region
_____ 6. Trapezius	F. Direction in which the muscle fibers run relative to some imaginary line
_____ 7. Rectus femoris	G. Relative size of the muscle
_____ 8. External oblique	

## GROSS ANATOMY OF THE SKELETAL MUSCLES

### Muscles of the Head

18. Identify the major muscles described in Column A by choosing a response from Column B. Enter the correct letter in the answer blank. Select a different color for each muscle described and color in the coding circle and corresponding muscle on Figure 6-6.

<b>Column A</b>	<b>Column B</b>
<input type="radio"/> _____ 1. Used to show you're happy	A. Buccinator
<input type="radio"/> _____ 2. Used to suck in your cheeks	B. Frontalis
<input type="radio"/> _____ 3. Used in winking	C. Masseter
<input type="radio"/> _____ 4. Wrinkles the forehead horizontally	D. Orbicularis oculi
<input type="radio"/> _____ 5. The "kissing" muscle	E. Orbicularis oris
<input type="radio"/> _____ 6. Prime mover of jaw closure	F. Sternocleidomastoid
<input type="radio"/> _____ 7. Synergist muscle for jaw closure	G. Temporalis
<input type="radio"/> _____ 8. Prime mover of head flexion; a two-headed muscle	H. Trapezius
	I. Zygomaticus



**Figure 6-6**

19. Match the muscle names in Column B to the facial muscles described in Column A.

Column A	Column B
_____ 1. Squints the eyes	A. Buccinator
_____ 2. Pulls the eyebrows superiorly	B. Frontal belly of the epicranium
_____ 3. Smiling muscle	C. Occipital belly of the epicranium
_____ 4. Puckers the lips	D. Orbicularis oculi
_____ 5. Draws the corners of the lips downward	E. Orbicularis oris
_____ 6. Pulls the scalp posteriorly	F. Platysma
	G. Zygomaticus

### Muscles of the Trunk

20. Identify the anterior trunk muscles described in Column A by choosing a response from Column B. Enter the correct letter in the answer blank. Then, for each muscle description that has a color-coding circle, select a different color to color the coding circle and corresponding muscle on Figure 6-7.

Column A	Column B
<input type="radio"/> _____ 1. The name means "straight muscle of the abdomen"	A. Deltoid
<input type="radio"/> _____ 2. Prime mover for shoulder flexion and adduction	B. Diaphragm
<input type="radio"/> _____ 3. Prime mover for shoulder abduction	C. External intercostal
<input type="radio"/> _____ 4. Part of the abdominal girdle; forms the external lateral walls of the abdomen	D. External oblique
<input type="radio"/> _____ 5. Acting alone, each muscle of this pair turns the head toward the opposite shoulder	E. Internal intercostal
_____ 6. and 7. Besides the two abdominal muscles (pairs) named above, two muscle pairs that help form the natural abdominal girdle	F. Internal oblique
_____ 8. Deep muscles of the thorax that promote the inspiratory phase of breathing	G. Latissimus dorsi
_____ 9. An unpaired muscle that acts with the muscles named immediately above to accomplish inspiration	H. Pectoralis major
	I. Rectus abdominis
	J. Sternocleidomastoid
	K. Transversus abdominis

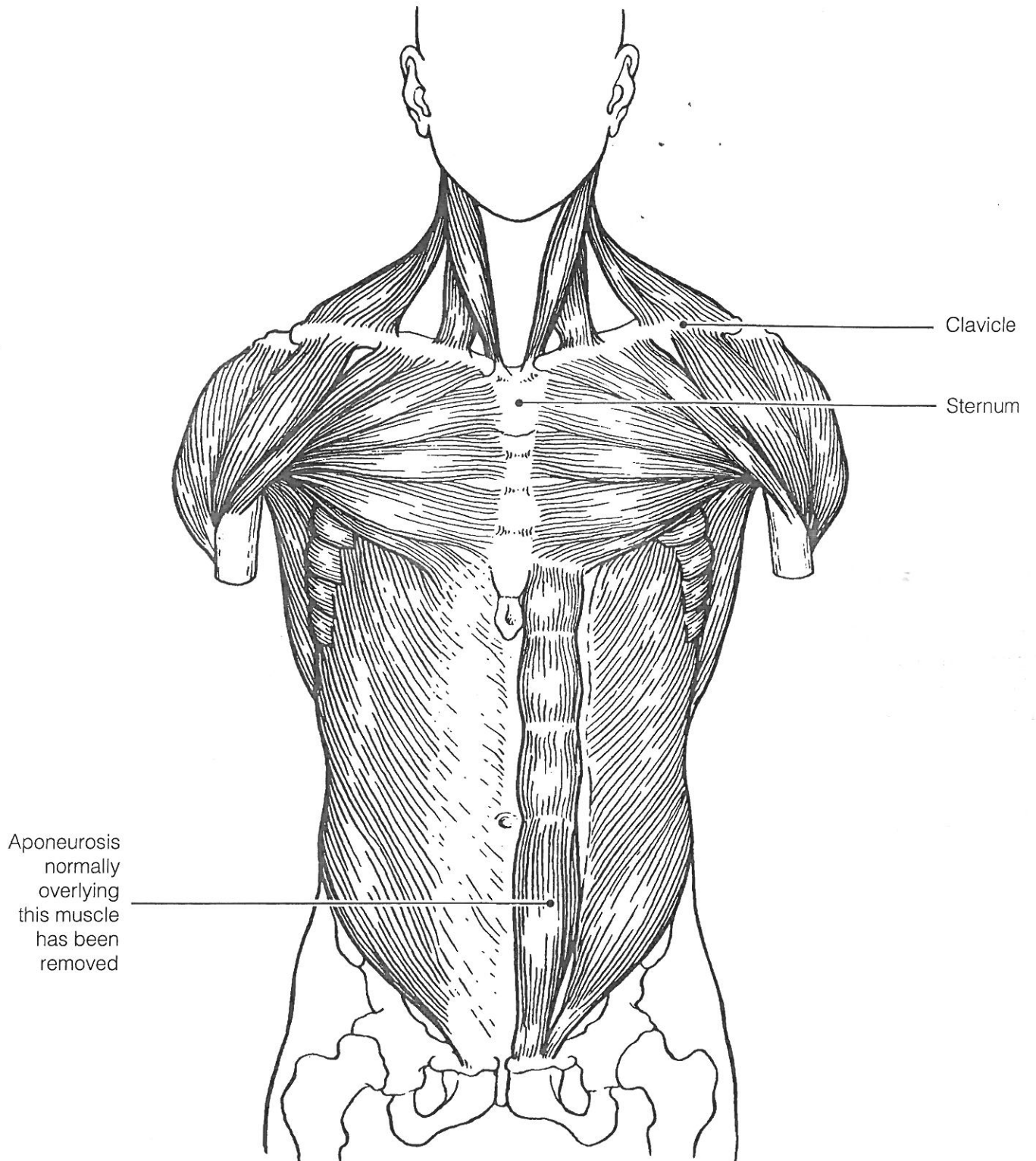


Figure 6-7

21. Identify the posterior trunk muscles described in Column A by choosing a response from Column B. Enter the correct letter in the answer blank. Select a different color for each muscle description with a coding circle and color the coding circles and corresponding muscles on Figure 6-8.

**Column A**

- \_\_\_\_\_ 1. Muscle that allows you to shrug your shoulders or extend your head
- \_\_\_\_\_ 2. Muscle that adducts the shoulder and causes extension of the shoulder joint
- \_\_\_\_\_ 3. Shoulder muscle that is the antagonist of the muscle just described
- \_\_\_\_\_ 4. Prime mover of back extension; a deep composite muscle consisting of three columns
- \_\_\_\_\_ 5. Large paired superficial muscle of the lower back
- \_\_\_\_\_ 6. Fleshy muscle forming part of the posterior abdominal wall that helps maintain upright posture

**Column B**

- A. Deltoid
- B. Erector spinae
- C. External oblique
- D. Gluteus maximus
- E. Latissimus dorsi
- F. Quadratus lumborum
- G. Trapezius

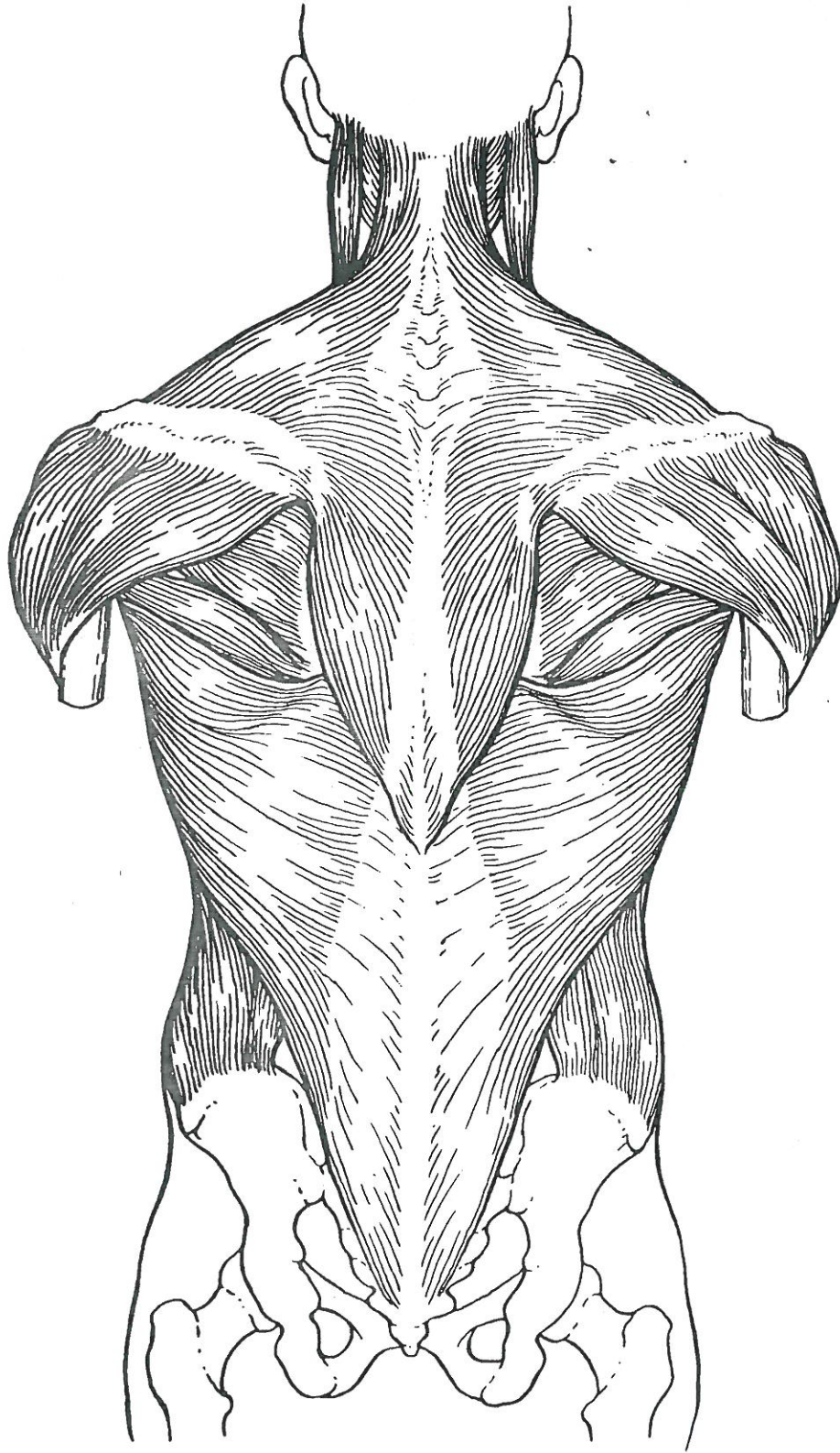


Figure 6-8

## Muscles of the Hip, Thigh, and Leg

22. Identify the muscles described in Column A by choosing a response from Column B. Enter the correct letter in the answer blank. Select a different color for each muscle description provided with a color-coding circle, and use it to color the coding circles and corresponding muscles on Figure 6–9. Complete the illustration by labeling those muscles provided with leader lines.

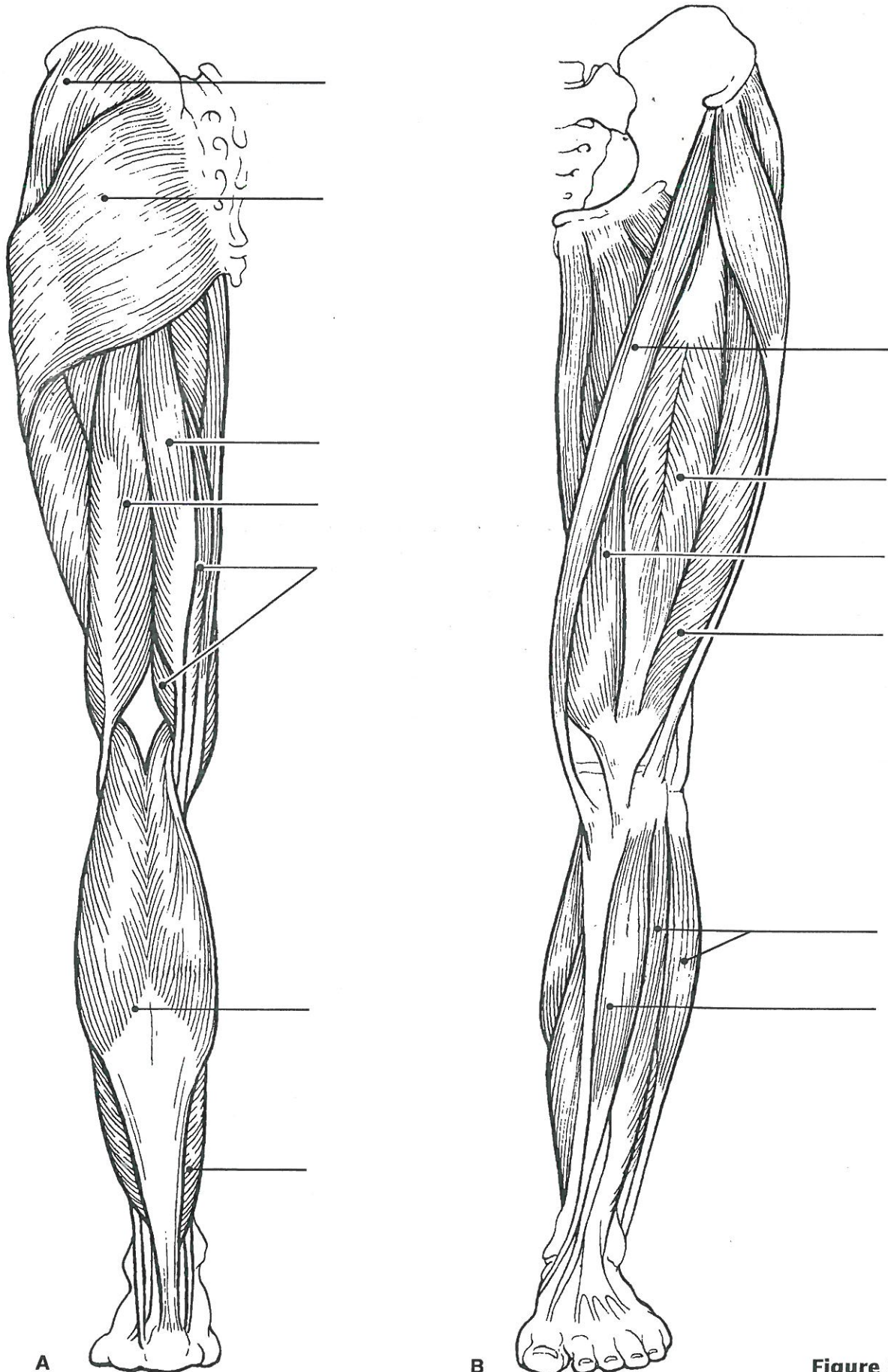
### Column A

- \_\_\_\_\_ 1. Hip flexor, deep in pelvis; a composite of two muscles
- \_\_\_\_\_ 2. Used to extend the hip when climbing stairs
- \_\_\_\_\_ 3. “Toe dancer’s” muscle; a two-bellied muscle of the calf
- \_\_\_\_\_ 4. Inverts and dorsiflexes the foot
- \_\_\_\_\_ 5. Muscle group that allows you to draw your legs to the midline of your body, as when standing at attention
- \_\_\_\_\_ 6. Muscle group that extends the knee
- \_\_\_\_\_ 7. Muscle group that extends the thigh and flexes the knee
- \_\_\_\_\_ 8. Smaller hip muscle commonly used as an injection site
- \_\_\_\_\_ 9. Muscle group of the lateral leg; plantar flex and evert the foot
- \_\_\_\_\_ 10. Straplike muscle that is a weak thigh flexor; the “tailor’s muscle”
- \_\_\_\_\_ 11. Like the two-bellied muscle that lies over it, this muscle is a plantar flexor

### Column B

- A. Adductors
- B. Biceps femoris
- C. Fibularis muscles
- D. Gastrocnemius
- E. Gluteus maximus
- F. Gluteus medius
- G. Hamstrings
- H. Iliopsoas
- I. Quadriceps
- J. Rectus femoris
- K. Sartorius
- L. Semimembranosus
- M. Semitendinosus
- N. Soleus
- O. Tibialis anterior
- P. Vastus intermedius
- Q. Vastus lateralis
- R. Vastus medialis

23. What is the functional reason the muscle group on the dorsal leg (calf) is so much larger than the muscle group in the ventral leg region?



A

B

Figure 6-9



## Muscles of the Arm and Forearm

24. Identify the muscles described in Column A by choosing a response from Column B. Enter the correct letter in the answer blank. Then select different colors for each muscle description provided with a color-coding circle and use them to color in the coding circles and corresponding muscles on Figure 6–10.

### Column A

- \_\_\_\_\_ 1. Wrist flexor that follows the ulna
- \_\_\_\_\_ 2. Muscle that extends the fingers
- \_\_\_\_\_ 3. Muscle that flexes the fingers
- \_\_\_\_\_ 4. Muscle that allows you to bend (flex) the elbow
- \_\_\_\_\_ 5. Muscle that extends the elbow
- \_\_\_\_\_ 6. Powerful shoulder abductor, used to raise the arm overhead

### Column B

- A. Biceps brachii
- B. Deltoid
- C. Extensor carpi radialis
- D. Extensor digitorum
- E. Flexor carpi ulnaris
- F. Flexor digitorum superficialis
- G. Triceps brachii

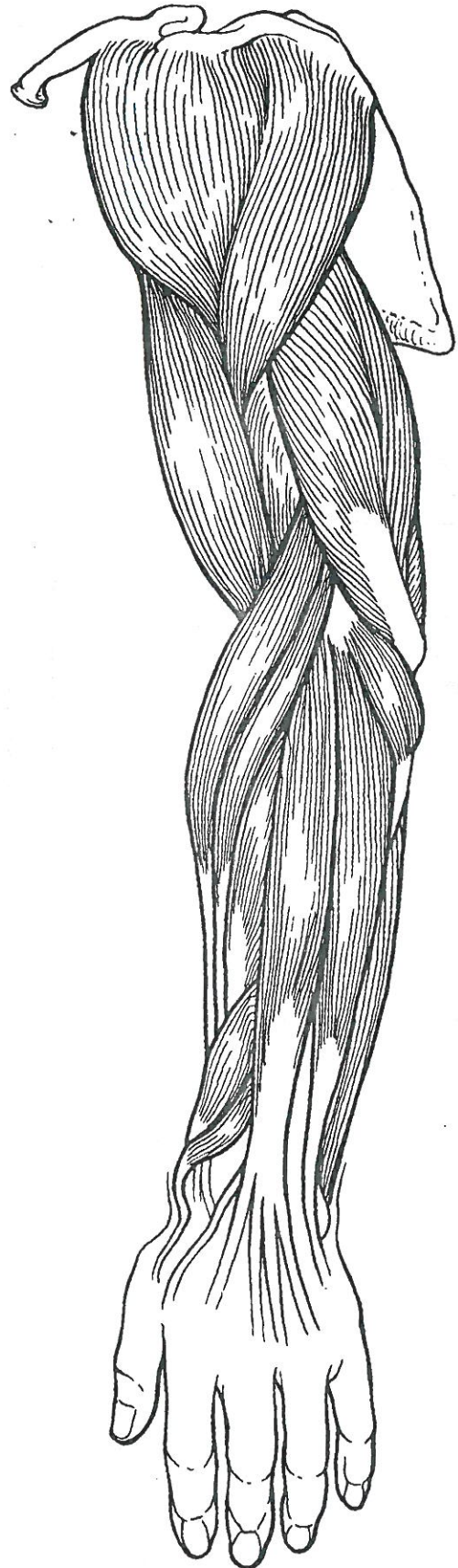

Figure 6–10

## General Body Muscle Review

25. Complete the following statements describing muscles. Insert the correct answers in the answer blanks.

- \_\_\_\_\_ 1. Three muscles— (1) , (2) , and (3) —are commonly used for intramuscular injections in adults.
- \_\_\_\_\_ 2. \_\_\_\_\_ 3. The insertion tendon of the (4) group contains a large sesamoid bone, the patella.
- \_\_\_\_\_ 4. The triceps surae insert in common into the (5) tendon.
- \_\_\_\_\_ 5. The bulk of the tissue of a muscle tends to lie (6) to the part of the body it causes to move.
- \_\_\_\_\_ 6. \_\_\_\_\_ 7. The extrinsic muscles of the hand originate on the (7).
- \_\_\_\_\_ 8. Most flexor muscles are located on the (8) aspect of the body; most extensors are located (9). An exception to this generalization is the extensor-flexor musculature of the (10).
- \_\_\_\_\_ 9. \_\_\_\_\_ 10. The pectoralis major and deltoid muscles act synergistically to (11) the arm.
- \_\_\_\_\_ 11.

26. Circle the term that does not belong in each of the following groupings.

1. Vastus lateralis      Vastus medialis      Knee extension      Biceps femoris
2. Latissimus dorsi      Pectoralis major      Shoulder adduction      Antagonists
3. Buccinator      Frontalis      Masseter      Mastication      Temporalis
4. Vastus medialis      Rectus femoris      Iliacus      Origin on coxal bone

27. When kicking a football, at least three major actions of the lower limb are involved. Name the major muscles (or muscle groups) responsible for the following:

1. Flexing the hip joint: \_\_\_\_\_
  2. Extending the knee: \_\_\_\_\_
  3. Dorsiflexing the foot: \_\_\_\_\_
- \_\_\_\_\_

28. Identify the numbered muscles in Figure 6–11 by placing the numbers in the blanks next to the following muscle names. Then select a different color for each muscle provided with a color-coding circle and color the coding circle and corresponding muscle in Figure 6–11.

- \_\_\_\_ 1. Orbicularis oris
- \_\_\_\_ 2. Pectoralis major
- \_\_\_\_ 3. External oblique
- \_\_\_\_ 4. Sternocleidomastoid
- \_\_\_\_ 5. Biceps brachii
- \_\_\_\_ 6. Deltoid
- \_\_\_\_ 7. Vastus lateralis
- \_\_\_\_ 8. Frontalis
- \_\_\_\_ 9. Rectus femoris
- \_\_\_\_ 10. Sartorius
- \_\_\_\_ 11. Gracilis
- \_\_\_\_ 12. Adductor group
- \_\_\_\_ 13. Fibularis longus
- \_\_\_\_ 14. Temporalis
- \_\_\_\_ 15. Orbicularis oculi
- \_\_\_\_ 16. Zygomaticus
- \_\_\_\_ 17. Masseter
- \_\_\_\_ 18. Vastus medialis
- \_\_\_\_ 19. Tibialis anterior
- \_\_\_\_ 20. Transversus abdominis
- \_\_\_\_ 21. Rectus abdominis

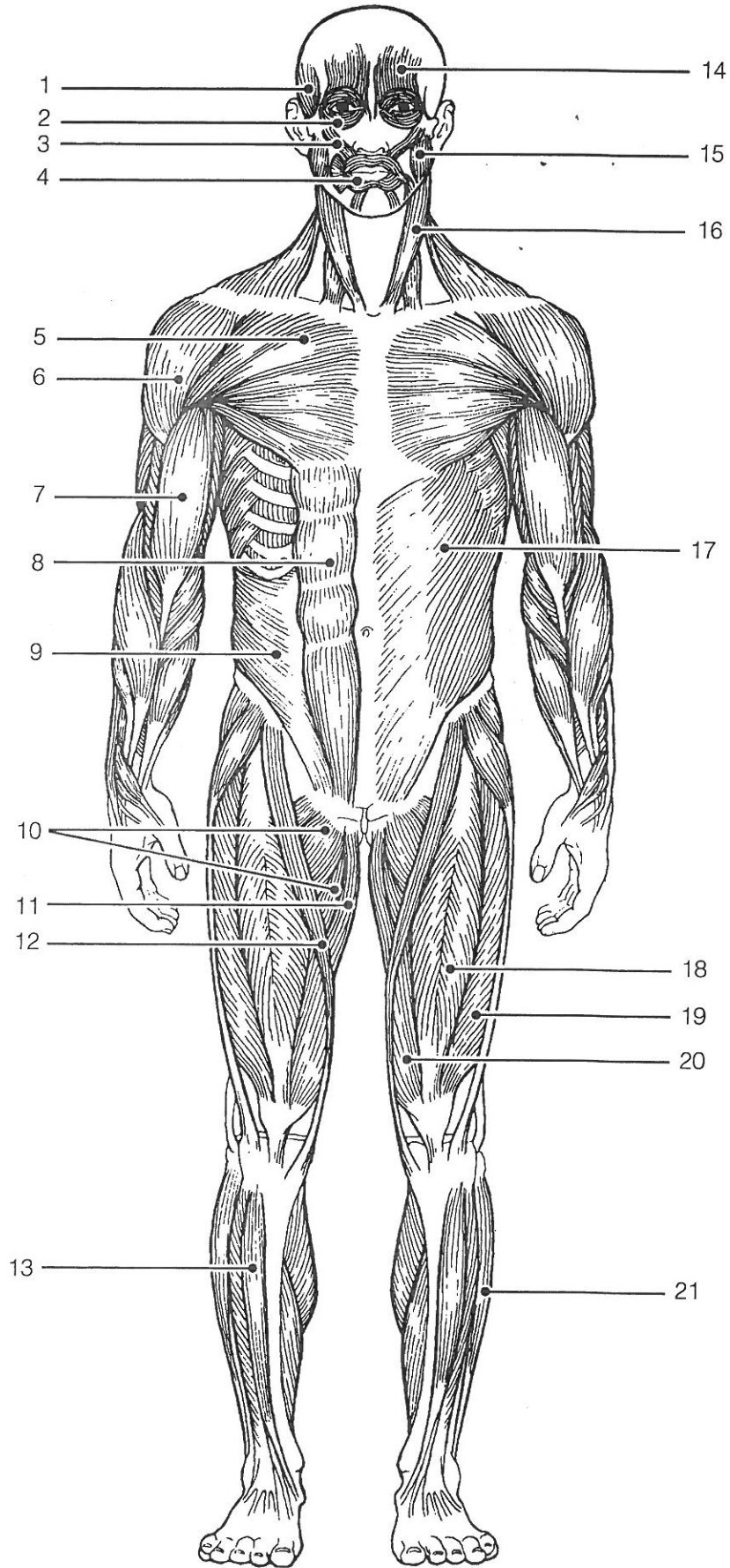


Figure 6-11