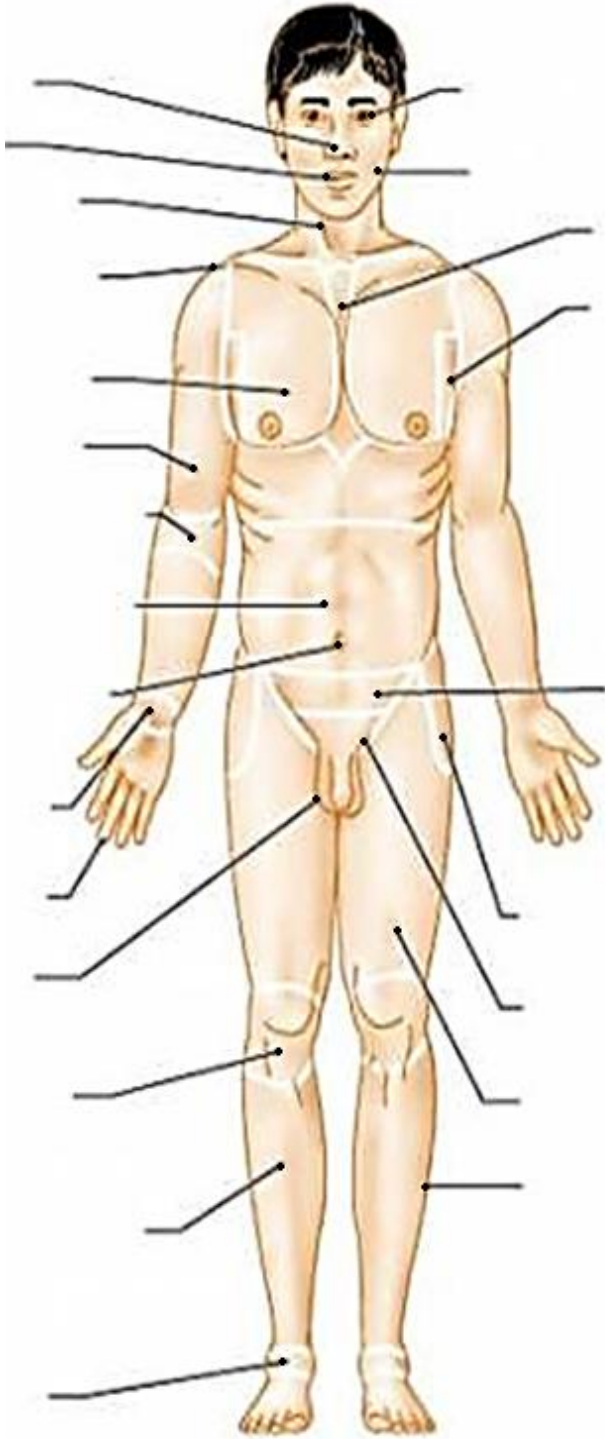


Name \_\_\_\_\_

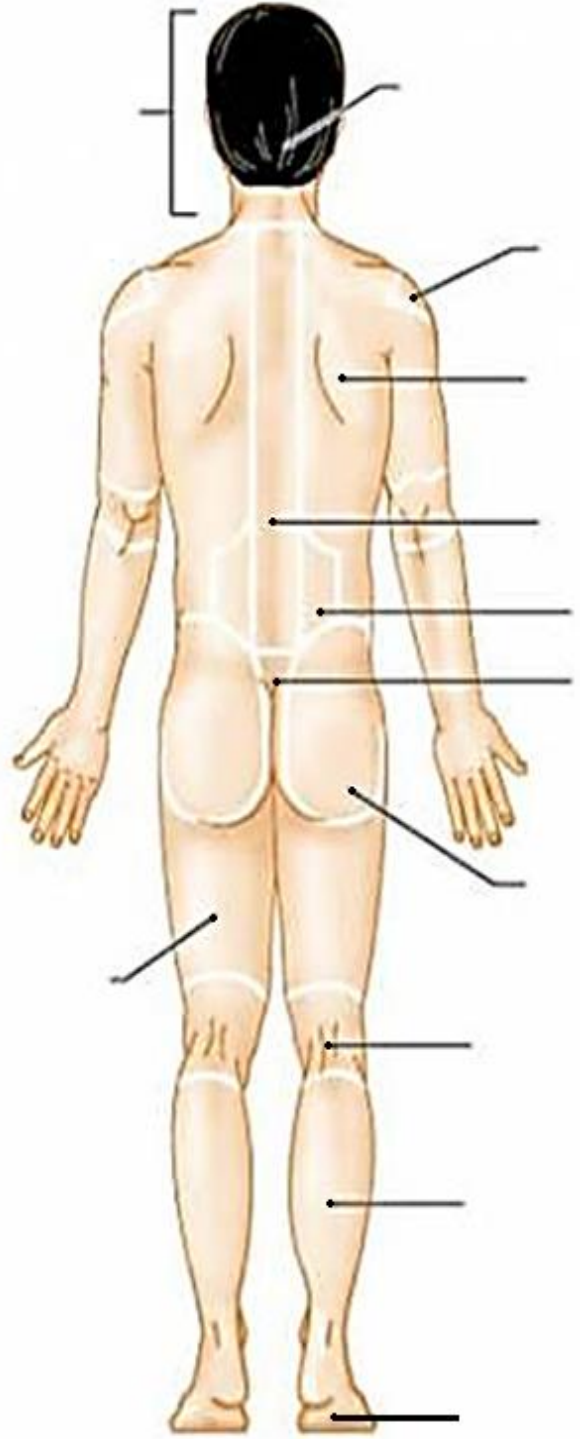
Date \_\_\_\_\_

### CHAPTER 1 REVIEW: The Language of Anatomy

Identify the structures with leader lines.



**(a) Anterior**



**(b) Posterior**